

# Endoscopic Management of Attic Cholesteatoma

## A Single-Institution Experience

Daniele Marchioni, MD\*, Domenico Villari, MD,  
Francesco Mattioli, MD, Matteo Alicandri-Ciuffelli, MD,  
Alessia Piccinini, MD, Livio Presutti, MD

### KEYWORDS

- Transcanal endoscopic approach • Cholesteatoma • Attic retraction
- Middle ear surgery • Residual • Recurrence

### KEY POINTS

- Most spaces considered to be difficult to access with the microscopic technique could be easily visualized by endoscope-assisted surgery.
- The surgical approach should be tailored to the anatomic and physiologic concepts behind the genesis of the attic cholesteatoma, respecting as much as possible the physiology and anatomy of the middle ear.
- Middle ear folds may play an important role in the blockage of ventilation routes, possibly provoking sectorial epitympanic dysventilation.
- When isthmus blockage occurs, ventilation of the epitympanum may be impaired, and the only gas exchange would come from the mucosa of mastoid cells, excluding air provision from the Eustachian tube.

### INTRODUCTION

Surgical management of cholesteatoma remains a controversial issue. Classical concepts are based on microscopic surgical management, as is the traditional classification of open tympanoplasties (canal wall down [CWD]) and closed tympanoplasties (canal wall up [CWU]), depending on the preservation of the posterior ear canal wall. The choice between these 2 techniques is based on several factors, although in most cases, the main factors influencing surgeons' ultimate attitude toward surgical management of cholesteatoma are their experience, personal beliefs, and confidence with each technique.

---

All the authors have read and approved the manuscript. The authors have no financial relationship to disclose.

Otolaryngology Department, University Hospital of Modena, Via del Pozzo 71, Modena 41100, Italy

\* Corresponding author.

E-mail address: [marchionidaniele@yahoo.it](mailto:marchionidaniele@yahoo.it)

Otolaryngol Clin N Am 46 (2013) 201–209  
<http://dx.doi.org/10.1016/j.otc.2012.10.004>

[oto.theclinics.com](http://oto.theclinics.com)

0030-6665/13/\$ – see front matter © 2013 Elsevier Inc. All rights reserved.

Endoscopic instrumentation, techniques, and knowledge have really improved during the past few years, and we believe that, in the future, endoscopic surgical techniques will gain increasing importance in otologic surgery. From our 7-year experience in endoscopic ear surgery, we believe that most of the spaces considered to be difficult to access with the microscopic technique could be easily visualized by endoscope-assisted surgery and we feel that new anatomic concepts should be introduced in preparation for this. From this perspective, classical concepts of CWU and CWD tympanoplasty could be completely changed in clinical practice.

When a new technique is introduced, acceptable results are essential to have it accepted by the scientific community. Because endoscopic ear surgery is a relatively “just-born” technique, only few articles reporting results are present in the literature.<sup>1,2</sup> This article illustrates the principles and results at our institution regarding endoscopic treatment of attic cholesteatoma.

## MATERIAL AND METHODS

In January 2006, a database was created by the authors D.V. and D.M., in which all patients operated for middle ear surgery were included and followed up at our clinic by regular visits at appropriate timing (generally, after 1, 3, 6, and 12 months from the operation, then annually). At follow-up, patients were evaluated by endoscopic office examination. Noted in the database were recurrences (defined as non-self cleaning re-retraction of the attic requiring surgery) and residuals (defined as insufficient primary resection of the epidermal matrix, presenting in absence of re-retraction of the tympanic membrane). Residuals were also defined by computed tomographic evaluations, performed most frequently at 1-year follow-up. In May 2012, the database was reviewed and 321 endoscopic procedures for middle ear pathologic condition were analyzed. Of these, 253 were middle ear cholesteatomas. For the present study, only attic cholesteatomas treated endoscopically (exclusively or combined) with at least 1.5 years of follow-up were included for further analyses. Patients who had prior middle ear operations at clinical history were excluded from the analyses.

## STATISTICAL ANALYSIS

Pearson correlation coefficient was used to evaluate the correlation between the absence or presence of disease (residual or recurrence) and age of patients (less than or greater than age 18 years) or type of matrix (infiltrative or sac matrix), the correlation between the absence or the residual disease and the extent of disease (cholesteatoma limited to the attic, mesotympanum extension, antral extension, mastoid extension), and the correlation between the absence or the recurrence of disease and the kind of reconstruction (cartilage, bone or fascia). The software, SPSS Statistics, version 17.0 was used for statistical analyses.

## RESULTS

The final study group included 146 ears (from 146 patients). The mean follow-up was 31.2 months (DS  $\pm$  15.8). Of the 146 patients, 135 (92.5%) were free from disease at their last follow-up visit, 4 (2.7%) patients were diagnosed with recurrence, and 7 (4.8%) patients had residual disease (**Fig. 1**).

Of the 146 patients, 120 (82.2%) underwent exclusive endoscopic approach and 26 (17.8%) underwent an endoscopic approach combined with mastoidectomy (**Fig. 2**). Of 146 patients, 34 (23.3%) underwent a cholesteatoma limited exclusively to the

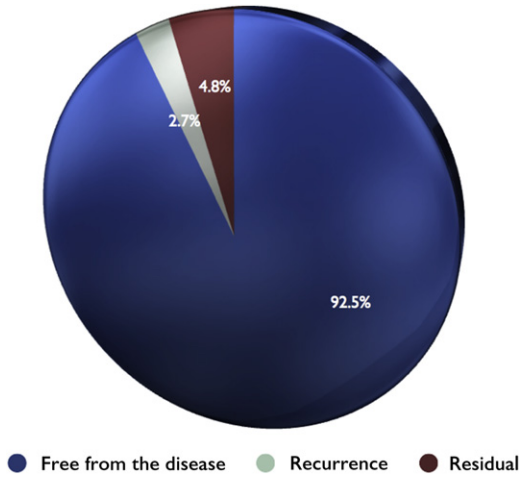


Fig. 1. Circular diagram showing the follow-up results.

attic, while 56 patients (38.4%) also had a mesotympanic extension of the disease, 32 (21.9%) had antral extension, and 24 (16.4%) had mastoid extension.

Of the 146 patients, 14 (9.6%) (Fig. 3) were younger than 18 years, whereas 132 (90.4%) were adults.

The cholesteatoma matrix was infiltrative in 117 of 146 patients (80.1%); 29 of 146 (19.9%) patients had a sac matrix. In 39 patients (26.7%), it was possible to avoid ossicular removal, whereas in 107 patients (73.3%), ossicular removal and reconstruction was necessary (in these cases, an ossicular chain erosion or an infiltrative matrix of the medial aspect of the ossicles was found). A total of 77 patients had a cartilage reconstruction of scutum (52.7%); in 21 patients, the reconstruction was performed by bone (14.4%) and in 48 (32.9%), by temporalis fascia (Figs. 4–6).

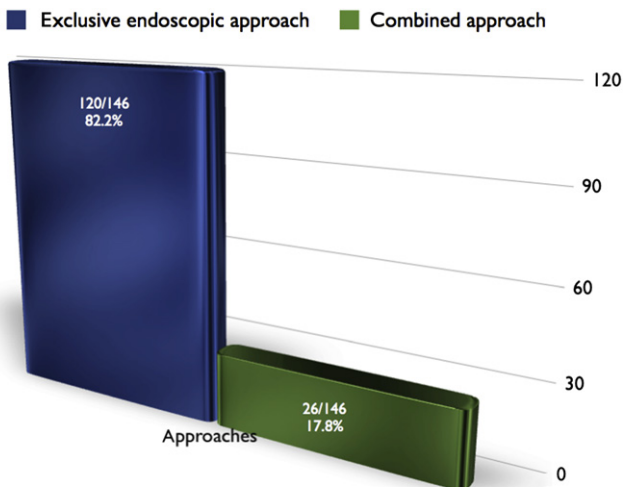
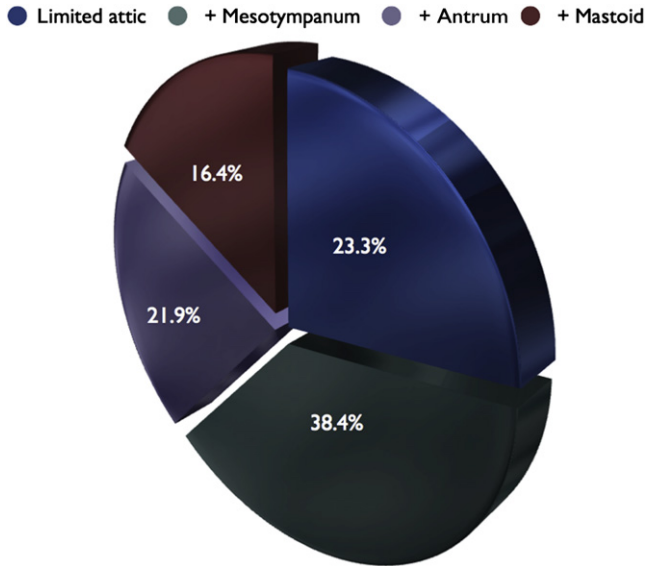



Fig. 2. Chart showing the surgical approaches.

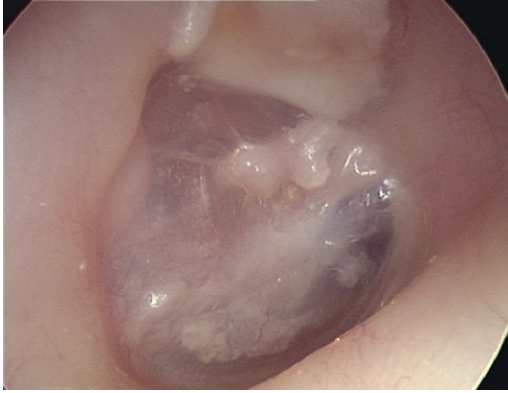

**Fig. 3.** Circular diagram showing the site of cholesteatoma; blue, limited to the attic; dark green, attic and mesotympanum; red, violet, attic and antrum; red, attic and mastoid.

Based on our statistical analyses, none of the variable analysis had a statistically significant impact on recurrence or residual. Regarding age (older or younger than 18 years), a recurrence or residual was present in 10 of 132 adult patients, whereas there was 1 case of recurrence of 14 patients aged younger than 18 years ( $P = .95$ ). Regarding the type of matrix, out of 28 patients with sac matrix, none experienced residual or recurrence, whereas 7 of 114 patients with infiltrative matrix experienced residual or recurrence ( $P = .17$ ). Of 33 patients with cholesteatoma limited exclusively to the attic, none experienced residual, and of 55 patients who also had



**Fig. 4.** Circular diagram showing the material used for scutum reconstruction.



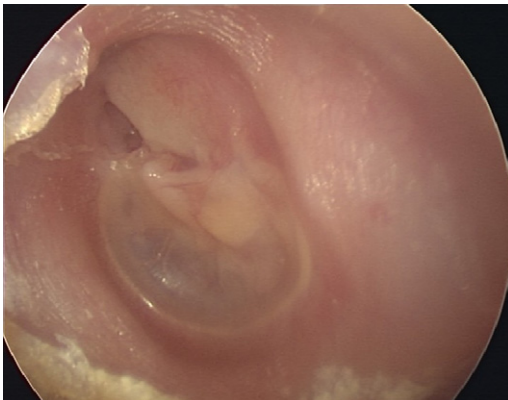
**Fig. 5.** Twenty-month follow-up of an exclusive endoscopic approach with cartilage scutum reconstruction.

a mesotympanic extension, 2 experienced residual pathologic condition at follow-up. Of 31 patients with antral extension, 2 experienced residual, and of 23 patients with mastoid extension, 3 experienced residual (overall  $P$  value considering subsite extension = 0.15). Of 75 patients who had a cartilage reconstruction of the scutum, 2 experienced recurrence; of 19 patients who had a bone reconstruction of the scutum, 1 experienced recurrence. Of 45 patients who had temporalis facia reconstruction, 1 experienced recurrence (overall  $P$  value considering reconstruction = 0.79).

## DISCUSSION

Primary acquired cholesteatoma is usually a manifestation of advanced retraction of the tympanic membrane that occurs when the sac advances into the tympanic cavity proper and then into its extensions such as the sinus tympani, the facial recess, the hypotympanum, and the attic.<sup>3</sup>

Only in advanced cases does a cholesteatoma progress further to reach the mastoid cavity. Most surgical failures associated with a postauricular approach seem to occur within the tympanic cavity, and it is difficult to reach that extension rather than the localization at the mastoid region.



**Fig. 6.** Twelve-month follow-up of a combined approach with cartilage scutum reconstruction.

The main problems regarding attic cholesteatoma removal are residual and recurrence.

Residual is due to insufficient primary resection of the epidermal matrix and classically presents a pearl-like appearance. Insufficient resection may be the result of a very fine epidermal matrix, middle ear inflammation, and particularly, a limited exposition of hidden areas such as epitympanic space and sinus tympani. The view during microscopic surgery is defined and limited by the narrowest segment of the ear canal; this basic limitation has forced surgeons to create a parallel port through the mastoid to gain keyhole access to the attic. Despite the illumination and magnification offered by the operating microscope, it has proved to have distinct limitations.

The surgeon can visualize structures only directly ahead and is unable to see “around-the-corner” objects. So this straight-line view offered by the microscope result in certain blind pockets during middle ear surgery. These limitations can be overcome with the complementary help of an endoscope.<sup>4</sup> Thomassin and colleagues<sup>5</sup> found that by using intraoperative endoscopy, the quality of disease eradication significantly improved and resulted in the decrease in incidence of residual cholesteatoma from 47% to 6%. Youssef and Poe<sup>6</sup> found that the use of the endoscopic technique significantly decreased the morbidity of the second-look procedure, enhanced visualization of residual disease, and reduced operating time. Badr-El-Dine<sup>7</sup> reported on the value of endoscopy as an adjunct in cholesteatoma surgery and documented a reduced risk of residuals when the endoscope was used. In the primary surgery, after completion of microscopic cleaning, the overall incidence of intraoperative residuals detected with the endoscope was 22.8%; sinus tympani was the most common site of intraoperative residuals in both CWU and CWD groups. At second-look endoscopic explorations, 8.6% of recurrences were identified.

The recurrence consists in a new dangerous tympanic retraction pocket caused by inadequate reconstruction of scutum and tympanic loss of substance, inducing persistence of the physiopathologic process of middle ear depression.

Recurrence can be diagnosed otoscopically, whereas residual cholesteatoma is classically independent of the eardrum and only surgical revision can determine definite diagnosis; this is the rationale of the second-look procedures, beside functional issues.<sup>8</sup> The persistence of physiopathologic phenomena, which had determined the cholesteatoma development, presents as a new attic retraction, which requires a further surgical approach to avoid the re-formation of attic cholesteatoma.

Cholesteatoma surgery primarily aims to eradicate the disease process and provide the patient with a safe and dry ear.

In cholesteatoma surgery, 2 competitive techniques have developed over the course of time:

1. Closed “CWU” tympanoplasty preserves physiologic epidermis migration from the inner portion of the external auditory canal and prevents infectious complications resulting from an unstable drainage cavity. These features make it the technique of choice in middle ear cholesteatoma. It entails, however, a risk of residual cholesteatoma ranging from 10% to 40%,<sup>9–13</sup> requiring radiological surveillance and/or second-look surgery, and this technique is not without recurrence rate.
2. Open “CWD” tympanoplasty allows excellent visualization of the disease with a proportionally good chance of complete removal but not without a residual rate, and it has a much less frequent recurrence rate. The disadvantage of the procedure is the lifelong need for frequent cleaning of the open cavity and water restrictions.

In the literature, several works<sup>5,7,14,15</sup> have focused on the intraoperative use of the endoscope during traditional microscopic CWU and CWD.

The endoscope-assisted surgery allows the surgeon to opt for a more conservative CWU, instead of CWD. Moreover, considering also that a CWD does not always allow exploration of hidden areas, the systematic intraoperative use of the endoscope is also useful in CWD mastoidectomy.<sup>15</sup>

Despite the anatomic and physiologic function of the connection between mastoid and middle ear, in both these surgical procedures, the surgeon needs to remove the mastoid cells and mucosa to reach the cholesteatoma from behind. From our 7-year experience in endoscopic ear surgery, we feel that new anatomic concepts should be introduced for better treating the pathologic condition of the ear. In this perspective, classical concepts of CWU and CWD tympanoplasties could be completely changed on clinical practice.

Despite the tools of choice, to be used during the surgery of the middle ear cholesteatoma, the surgical approach should be tailored to the anatomic and physiologic concepts that generate attic cholesteatoma, preserving as much as possible the physiology and the anatomy of the middle ear. These concepts may be crucial to get an optimal "functional result."

From our previous experiences,<sup>14,16</sup> the key in attic cholesteatoma is the correct comprehension of physiopathologic pathways. Epitympanum aeration is strictly dependent on the ventilation pathways clarified by Palva and Ramsay,<sup>17</sup> and possible selective dysventilation of epitympanic compartments could provoke attic retractions or cholesteatoma.

When an isthmus blockage occurs, ventilation of the epitympanum may be impaired, and the only gas exchange would come from the mucosa of mastoid cells, excluding air provision from the Eustachian tube. We recently studied middle ear ventilation route blockage and its relationship with mastoid pneumatization, and some different types of isthmus blockage, related to different pathologic conditions, were identified and classified.<sup>18</sup> Moreover, we found that obstruction of the tympanic isthmus is a consistent finding in patients affected by limited attic cholesteatoma.

In the past years, several studies have focused on evaluating the role of tympanic isthmus, especially in cadaveric dissection studies<sup>14,18</sup>; with the advent of endoscopic techniques, it has become possible to study the morphologic shape of the epitympanic diaphragm and tympanic isthmus in the pathologic ears especially in case of attic cholesteatoma. This would have been impossible by a microscope because of the angulation and the position of tympanic isthmus. From these studies, it was clear how, in patients with epitympanic cholesteatoma, a complete epitympanic diaphragm was present, associated to a total isthmus blockage, and this created a complete ventilatory exclusion of the epitympanic compartments from the mesotympanic spaces, causing a low ossigenation of the mucosa of the attic space and mastoid compartments, which is in general guaranteed by the Eustachian tube. The low ventilation would generate a progressive air reabsorption through the attic mucosa, creating a selective epitympanic negative pressure in the attic that could be the pathogenetic substrate for the complete pars flaccida retraction to the lateral attic space and the progressive formation of attic cholesteatoma. This could explain the typical clinical scenario of an attic cholesteatoma or attic retraction associated with the erosion of the scutum, with a normal shape and position of the pars tensa and without pathologic alteration in mesotympanum. Actually, middle ear folds may play an important role in the blockage of ventilation routes, possibly provoking sectorial epitympanic dysventilation.<sup>14,18</sup> So systematic intraoperative visualization, analysis, and in some cases, removal of these folds, should be mandatory in every procedure. Preservation of mastoid tissue may contribute to improvement of postoperative middle ear ventilation, because of their role in middle ear gas exchange. From these

concepts, we believe that the surgical approach to attic cholesteatoma should respect some conditions: disease eradication with direct access to the hidden areas, preservation of the mastoid cells and mucosa wherever possible, and restoration of the physiologic aeration pathways from the Eustachian tube to the attic, by removing the block of the isthmus and by creating additional aeration pathways through the tensor fold (which connects the protympanum to the anterior attic). From all these concepts, we strongly believe that we need to develop a direct surgical approach through the external auditory canal to the middle ear cholesteatoma, and the endoscope at present is the best tool to allow a direct access to the tympanic cavity areas, getting also a direct view of the isthmus and tensor fold areas. When cholesteatoma is limited to the tympanic cavity, the transcanal endoscopic approach allows the eradication of the disease, the ventilation routes being restored by removing the isthmus blockage and the tensor fold, while preserving the mastoid mucosa.

Exclusive endoscopic tympanoplasty was first described by Tarabichi.<sup>19</sup> The new concept of endoscopic ear surgery redirected the attention away from the less-critical areas (ie, mastoid) toward the tympanic cavity and its “hard-to-reach” extensions. The endoscopic technique was codified for a minimally invasive eradication of limited attic cholesteatoma, preserving the ossicular chain wherever possible with complete removal of the disease. From this indication, the clinical application of the transcanal endoscopic approach has allowed to extend the indication of this technique to cholesteatoma of the whole tympanic cavity without mastoid involvement.

Some disadvantages of endoscopic technique must be considered:

- The endoscopic approach is a “one-hand technique”; for this reason, surgeons need special learning curve to improve their personal skills.
- The mastoid is not accessible by the endoscope, and when the mastoid is involved with the cholesteatoma, a microscopic technique is required.

Regarding our results, none of the comparisons (matrix, age, subsite involvement, type of reconstruction) considered until now have reached a statistically significant value. The authors would attribute this finding more to the small sample size or to the rarity of the events (recurrence or residual) than to the real absence of differences between factors considered. The authors would like to underline that further experiences and longer follow-up are for sure necessary to confirm and underline factors possibly influencing results. Regarding recurrence rates and residual pathologic conditions, the “middle-term results” of our cohort of patients are completely similar to those reported in the literature for microscopic surgery of cholesteatoma, especially regarding the recurrence rate.

The authors are convinced that the main issue is the preservation of the graft used to reconstruct the scutum. Understanding the behavior and healing process of the graft during the follow-up time is crucial, to understand if the preservation of the buffer mastoid mechanism and the restoration of attic ventilation are useful to maintain the graft in the original position without developing recurrent attic retraction.

## SUMMARY

Endoscopic ear surgery can be considered an effective method to eradicate cholesteatoma from middle ear. It guarantees better visualization of hidden areas, better chances of tissue preservation, and minimally invasive access. It also allows better understanding of the pathophysiology of cholesteatoma, along with a detailed anatomic study. Results are comparable to those reported for microscopic techniques in terms of recurrences or residual pathology. Further experiences are necessary to confirm our results.



## REFERENCES

1. Migirov L, Shapira Y, Horowitz Z, et al. Exclusive endoscopic ear surgery for acquired cholesteatoma: preliminary results. *Otol Neurotol* 2011;32(3):433–6.
2. Tarabichi M. Endoscopic management of cholesteatoma: long-term results. *Otolaryngol Head Neck Surg* 2000;122(6):874–81.
3. Sheehy JL, Brackmann DE, Graham MD. Cholesteatoma surgery: residual and recurrent disease. A review of 1,024 cases. *Ann Otol Rhinol Laryngol* 1977;86:451–62.
4. Magnan J, Chays A, Lepetre C, et al. Surgical perspectives of endoscopy of the cerebellopontine angle. *Am J Otol* 1994;15:366–70.
5. Thomassin JM, Korchia D, Doris JM. Endoscopic-guided otosurgery in the prevention of residual cholesteatomas. *Laryngoscope* 1993;103:939–43.
6. Youssef TF, Poe DS. Endoscope-assisted second-stage tympanomastoidectomy. *Laryngoscope* 1997;107:1341–4.
7. Badr-el-Dine M. Value of ear endoscopy in cholesteatoma surgery. *Otol Neurotol* 2002;23:631–5.
8. Gaillardin L, Lescanne E, Morinière S, et al. Residual cholesteatoma: prevalence and location. Follow-up strategy in adults. *Eur Ann Otorhinolaryngol Head Neck Dis* 2012;129(3):136–40.
9. Haginomori S, Takamaki A, Nonaka R, et al. Residual cholesteatoma: incidence and localization in canal wall down tympanoplasty with soft-wall reconstruction. *Arch Otolaryngol Head Neck Surg* 2008;134:652–7.
10. Barakate M, Bottrill I. Combined approach tympanoplasty for cholesteatoma: impact of middle ear endoscopy. *J Laryngol Otol* 2008;122:120–4.
11. Hinohira Y, Yanahigara N, Gyo K. Improvements to staged canal wall up tympanoplasty for middle ear cholesteatoma. *Otolaryngol Head Neck Surg* 2007;137:913–7.
12. Hamilton JW. Efficacy of the KTP laser in the treatment of middle ear cholesteatoma. *Otol Neurotol* 2005;26:135–9.
13. Yung MW. The use of middle ear endoscopy: has residual cholesteatoma been eliminated? *J Laryngol Otol* 2001;115:958–61.
14. Marchioni D, Mattioli F, Alicandri Ciufelli M, et al. Endoscopic approach to tensor fold in patients with attic cholesteatoma. *Acta Otolaryngol* 2009;129:946–54.
15. Presutti L, Marchioni D, Mattioli F, et al. Endoscopic management of acquired cholesteatoma: our experience. *J Otolaryngol Head Neck Surg* 2008;37(4):481–7.
16. Marchioni D, Alicandri Ciufelli M, Molteni G, et al. Selective epitympanic dysventilation syndrome. *Laryngoscope* 2010;120:1028–33.
17. Palva T, Ramsay H. Chronic inflammatory ear disease and cholesteatoma: creation of auxiliary attic aeration pathways by microdissection. *Am J Otol* 1999;20:145–51.
18. Marchioni D, Mattioli F, Alicandri-Ciufelli M, et al. Endoscopic evaluation of middle ear ventilation route blockage. *Am J Otolaryngol* 2010;31(6):453–66.
19. Tarabichi M. Endoscopic management of acquired cholesteatoma. *Am J Otol* 1997;18:5444–9.